

CASE REPORT

***Bartonella henselae* AS A PUTATIVE CAUSE OF CONGENITAL CHOLESTASIS**

Paulo Eduardo Neves Ferreira VELHO(1), Maria Ângela BELLOMO-BRANDÃO(2), Marina Rovani DRUMMOND(1), Renata Ferreira MAGALHÃES(1), Gabriel HESSEL(2), Maria de Lourdes BARJAS-CASTRO(1), Cecília Amélia Fazzio ESCANHOELA(3), Gilda Maria Barbaro DEL NEGRO(4) & Thelma Suely OKAY(5)

SUMMARY

Severe anemia and cholestatic hepatitis are associated with bartonella infections. A putative vertical *Bartonella henselae* infection was defined on the basis of ultrastructural and molecular analyses in a three-year-old child with anemia, jaundice and hepatosplenomegaly since birth. Physicians should consider bartonellosis in patients with anemia and hepatitis of unknown origin.

KEYWORDS: Bartonella; Hepatitis; Cholestasis; Disease Transmission; Infectious.

INTRODUCTION

Bartonella spp. are emerging bacterial pathogens. The clinical spectrum of human bartonellosis has increased rapidly and several species of this genus have already been associated with human infections^{1,2}. Cats comprise the most well-known and studied reservoirs. Abortion related to infection by *Bartonella henselae* has already been described in equines³. Bilavsky *et al.* (2012) related a case of one woman who presented with clinical cat scratch disease during the first month of pregnancy and had a spontaneous abortion⁴. Although vertical transmission in felines has not been documented, previously infected females have greater difficulty in becoming pregnant and maintaining their pregnancies⁵. Conversely, vertical transmission has been documented in mice experimentally infected with *Bartonella birtlesii*⁶. Breitschwerdt *et al.* (2010) showed molecular evidence of perinatal transmission of *Bartonella vinsonii* subsp. *berkhoffii* and *B. henselae* to a child⁷.

In a case-controlled study performed in HIV positive patients Mohle-Boetani *et al.* (1996) observed that anemia and elevated serum alkaline phosphatase were associated with *B. henselae* and *Bartonella quintana* infections⁸. Angiomatous proliferation and granulomatous reactions, severe anemia and cholestatic hepatitis are examples of the wide spectrum of clinical manifestations associated with *Bartonella* sp. infections⁹.

CASE REPORT

We report a case of a three-year-old child born to an asymptomatic woman and presenting with anemia, jaundice and hepatosplenomegaly since birth, whose putative vertically transmitted infection by *B. henselae* was defined on the basis of ultrastructural microscopy

findings in liver biopsy, and the molecular detection of *B. henselae* DNA directly from the mother's blood sample and also from the child's blood culture bottles that had yielded negative blood culture results. A full term white female neonate was delivered by C-section due to functional dystocia after a prenatal care without interurrences. The birth weight was 3,400 g and the Apgar scores were 8 and 10 in the first and fifth minutes, respectively. The mother was asymptomatic and had no morbid antecedents, although she reported domiciliary contact with cats prior to and throughout pregnancy.

At eight days of life she began to present with choluria and acholic stools. The abdominal ultrasound examination revealed absence of bile duct dilation and the presence of gallbladder hypocontractility. The child had remained hospitalized in the maternity ward where she was born until she was referred to the University of Campinas, Sao Paulo, Brazil, on the tenth day of life. At admission, the neonate presented with a urinary tract infection caused by *Enterobacter cloacae* which was successfully treated for 10 days with amikacin. At this time the hypothesis of trans-infectious hepatitis and cholestasis was considered. Acute infectious diseases were investigated and serology to search for anti-IgM antibodies were negative for cytomegalovirus (CMV), syphilis, HBV, HCV, and toxoplasmosis, with positive and low anti-IgG detection only for toxoplasmosis and CMV. A first percutaneous liver biopsy performed at 12 days of age evidenced a lobular neonatal cholestatic syndrome and the presence of a bile channel plug. Ursodeoxycholic acid was prescribed.

As the jaundice worsened and the liver enlarged at 30 days old the patient was submitted to a cholangiography that discarded the presence of bile-duct atresia. However, a second liver biopsy performed at this time indicated the presence of a lobular neonatal cholestatic syndrome,

(1) University of Campinas (UNICAMP) Medical Science School, Department of Medicine, Campinas, SP, Brazil.

(2) University of Campinas (UNICAMP) Medical Science School, Department of Pediatrics, Campinas, SP, Brazil.

(3) University of Campinas (UNICAMP) Medical Science School, Department of Pathology, Campinas, SP, Brazil.

(4) University of Sao Paulo (USP), School of Medicine and Institute of Tropical Medicine, Clinical Hospital, Division of Clinical Dermatology, Laboratory of Medical Mycology (LIM-53), Sao Paulo, SP, Brazil.

(5) University of Sao Paulo (USP), Institute of Tropical Medicine, Laboratory of Seroepidemiology and Immunobiology, Sao Paulo, SP, Brazil.

Correspondence to: Paulo E. N. F. Velho, Universidade Estadual de Campinas, Departamento de Medicina da Faculdade de Ciências Médicas (UNICAMP), Rua Tessália Vieira Camargo 126, Barão Geraldo 13084-971 Campinas, SP, Brasil. Cx.P. 6111, Tel.: 55 19 35217602. E-mail: pvelho@unicamp.br

some giant cells and ductopenia. A battery of tests was performed to exclude the most common inborn metabolic errors. A Na/Cl sweat test, an ophthalmologic exam, X-rays of the cranium, spine and chest were normal. The child evolved with clinical deterioration, increment of the anemia, jaundice, hepatosplenomegaly and choloria. The patient also developed thrombocytopenia, a leukemoid reaction, hypoalbuminemia and ascites. A myelogram was performed and showed an erythroid hyperplasia. Other laboratory parameters showed an indirect bilirubin of 15mg/dL and a direct bilirubin of 41.8 mg/dL. Tyrosinaemia was also excluded.

At two months old the infant underwent a third liver biopsy that corroborated the previous findings. Moreover, an accentuated giant cell transformation was observed and an extra hepatic cholestasis could not be discarded due to the lack of portal spaces. Therefore, at 77 days of age, due to three inconclusive liver percutaneous biopsies and the aggravation of the jaundice, a surgical liver biopsy was indicated to definitively confirm or exclude the diagnosis of a bile duct atresia (Fig. 1). The histological examination upheld the accentuated transformation of giant cells and the absence of any morphological hallmark morphological indicators of bile-duct atresia. The Transmission Electron Microscopy (TEM) did not show any evidence of metabolic diseases.

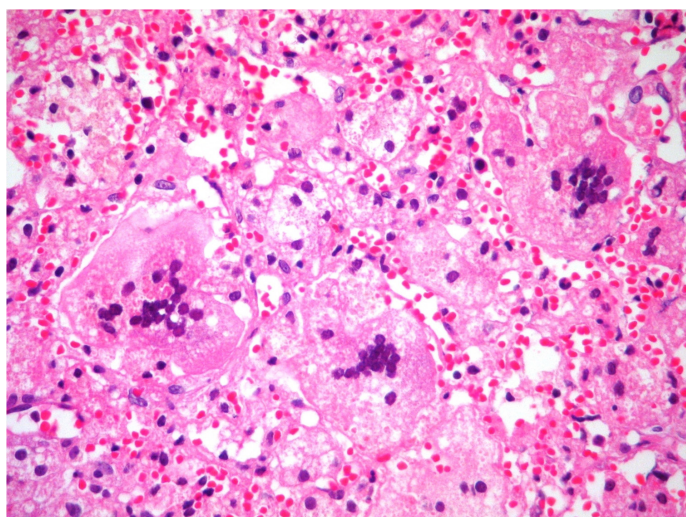


Fig. 1 - Marked transformation gigantocellular of hepatocytes (HE-400x)

In addition to the negative CMV serology (positive low IgG titers and negative IgM), a DNA-PCR-CMV was performed in the liver tissue and also resulted negative. Even so, as CMV is a frequent infectious agent associated with the neonatal cholestatic syndrome, the child had no confirmed diagnosis at that time and her clinical conditions were deteriorating, so that, a 21 days of treatment with ganciclovir was initiated at the third month of life, but resulted in no improvement of the clinical and laboratory parameters.

Therefore, the etiologic investigation proceeded. The anti-smooth muscle antibody test was positive (1:80), but the direct anti-human globulin test (Coombs) showed a negative result. The factor V (Leiden) level was 100%. Parvovirus infection was investigated by means of a DNA-PCR performed in a peripheral blood sample from the child and resulted negative.

A bone marrow biopsy was performed and showed a normocellular marrow for the patient's age, a moderate reduction in the granulocyte/erythrocyte ratio and a discrete delay of the erythroid series maturation.

A fifth liver biopsy was carried at three months old and it did not bring any new evidence. At that time, the diagnostic hypothesis was an autoimmune hepatitis, so the child was prescribed 2 mg/kg/day of prednisone and 1.5 mg/kg/day of azathioprine, and her serum had transaminases returned to normal levels, although the anemia had persisted.

Further investigation of hemolytic diseases was undertaken when she was four months old and showed a positive direct anti-globulin test with IgG and C3d, nevertheless the acid elution was negative. Biphasic hemolysin research also presented weak positive results. All the tests were repeated after four weeks and the results were negative. The paroxysmal nocturnal hemoglobinuria was also discarded due to a normal flow cytometry.

As a consequence of the persistent anemia, the first transfusion of Red Blood Cells (RBC) was performed when she was six months old (hemoglobin was 6.7 mg/dL) and from this period, RBC transfusions had to be performed every three or four weeks.

Medical interurrences during the first and the second years of life included the persistence of anemia and one episode of urinary tract infection caused by *Klebsiella* sp. which was successfully treated. A posterior ultrasound investigation of the kidneys and the urinary tract was normal as well as the voiding urethrocytography. Even though, the girl has received cephalosporin to prevent urinary tract infections.

At the age of three years, the patient still required nearly monthly RBC transfusions (without iron chelation) and continued to receive prednisone and azathioprine to control the hepatic auto-immune process. In order to continue the anemia investigation, a drop of child's blood was fixed in Karnovsky solution, then processed as previously described¹⁰ and examined by TEM. Structures inside erythrocytes with size and morphology compatible with Gram-negative bacteria were observed. The TEM of a deparaffined liver fragment from the first biopsy performed at 12 days of age has also evidenced the presence of a similar etiological agent within erythrocytes (Fig. 2).

At this time, the patient's mother decided to donate blood at the UNICAMP Blood Bank (HEMOCENTRO). As *Bartonella* sp. infection had been suggested to explain the persistent anemia, a TEM was performed in a drop of this donated blood showing the presence of rare RBC containing structures suggestive of Gram-negative bacteria¹¹.

In addition, one peripheral blood sample from the child was negative by a previously described one-round species-specific amplification targeting to the *B. henselae* *FtsZ* gene¹².

Due to the mother and the child TEM findings supporting the diagnosis of bartonellosis, the girl was treated with oral erythromycin for 14 days evolving with a mild improvement of the anemia.

She was readmitted 30 days later and a fifth new liver biopsy was performed and still showed the presence of giant cells. At this time, by the systemic and severe involvement she began an intravenous antibiotic

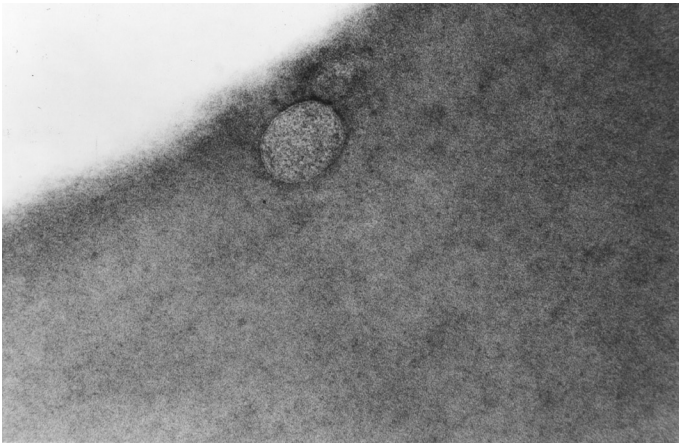


Fig. 2 - Transmission electron micrography of a deparaffined liver fragment from the biopsy performed at 12 days of age shows an erythrocyte containing an organism with typical trilaminar cell wall structure

therapy with gentamicin (7mg/kg/day) for 14 days and erythromycin (50mg/kg/day) for 28 days. After two weeks, there was a partial regression of the hepatosplenomegaly with subsequent reduction of the abdominal volume and after the 28 days of intravenous antibiotic treatment with gentamicin and erythromycin, there was a transitory reduction of the patient's need for transfusion and we could discontinue the prednisone and azathioprine without new increments of the hepatic enzymes. The hemoglobin at admission was 8 g/dL and, at the end of the hospital stay, 6g/dL so that the patient was once again transfused before she was discharged with a two month prescription of oral azithromycin. Afterwards, she returned to the oral erythromycin regimen until the completion of splenectomy eight month later. After that, the patient did not require further blood transfusions. The liver fragments collected during the splenectomy showed chronic liver disease with portal enlargement and portal-portal septa, haemosiderosis as well as severe myeloid metaplasia. No giant cells were observed.

In an attempt to confirm the TEM findings, considering that all the blood cultures of the child were negative, including those performed in special culture media to isolate *Bartonella* spp., a nested-*FtsZ*-PCR was standardized and used to test eleven stored blood samples of the child collected before the prescription of antibiotics to treat the bartonellosis at three years of age. The outer primers being the same that had already been described¹² and were coupled to a second amplification with newly designed inner primers¹³: forward-CAAAACGGTTGGAGAGCAGT and reverse-CGCCTGTCATCTCATCAAGA. Aside from the child's eleven blood samples, one aliquot of the mother's blood from the donated blood bag was also tested¹¹. Unfortunately, neither the fragments of the liver biopsies nor the placenta were available for amplification. Only the mother's blood from the donated bag was positive by the nested-*FtsZ* PCR for *B. henselae*. However, eleven peripheral blood samples from the child that had been diluted in BACTEC bottles to perform the blood cultures and stored after the final negative blood culture result were also tested. Some of them were collected when the patient was under antibiotic treatment. Three of these eleven samples were positive by the species-specific *B. henselae* nested-*FtsZ* PCR. The amplification products were submitted to enzyme restriction with HpyCH4IV (New England Biolabs, Ipswich, USA) to confirm the specificity of amplifications,

generating two fragments of 127 and 91 bp, as expected for *B. henselae*. The entire amplification products were also submitted to an automated DNA sequencing (ABI 3100, Applied Biosystems, USA) and showed that the *FtsZ* DNA fragments of the mother and her daughter were 100% homologous with the Houston 1 strain (GenBank accession number BX897699).

The child is currently 12 years old and is under benzathine penicillin treatment schedule every 21 days due to the splenectomy. She has been monitored ever since without other infectious episodes.

DISCUSSION

Several diagnostic hypotheses were made as this patient's case evolved. Initially a transinfectious cholestasis due to a urinary tract infection was considered¹⁴. However, the patient cholestasis did not improve after the successful treatment. The histological examination revealed morphological alterations suggestive of neonatal hepatitis. Since discrete ductopenia was considered in the first biopsy, the concern was to discard the association with an infectious agent, or alternatively with genetic conditions such as the Alagille syndrome or the alpha-1 antitrypsin deficiency¹⁵. The specific investigation of these syndromes turned up negative and ductopenia was not confirmed.

As the case evolved, clinical features worsened with jaundice becoming accentuated. At this point, the hypothesis that needed to be discarded was a hepatitis induced bile-duct atresia. The intra-operative cholangiography and surgical liver biopsy, once again, discarded this hypothesis.

Following this, the persistence of the anemia and the liver biopsies showing an accentuated number of giant cells lead to a new diagnostic hypothesis of hepatitis associated with an immune hemolytic anemia. It is known that the presence of giant cells is characteristic of several hepatic injuries taking place during the prenatal period, caused by CMV, rubella, herpes simplex, treponema, paramyxoviruses, autoimmune diseases, metabolic diseases and drugs.

The presence of a hemolytic anemia associated with giant cells in the liver identifies a pathologic condition first described by Bernard *et al.* (1981)¹⁶ who reported four cases, three of which with fatal outcome. In the currently described patient her clinical/laboratory parameters were compatible with this diagnosis, excepting for the negative direct anti-human globulin test (Coombs)¹⁶⁻¹⁸.

The patient began the treatment with immunosuppressive drugs and the exams revealed a decrease in liver transaminases, however the anemia persisted. This behavior has been previously observed in a case reported by Gorelik *et al.* (2004) in which a good therapeutic response was obtained with the administration of anti-CD20 antibodies¹⁹. In the present patient, the anti-CD20 was not used because the etiology was not formally defined.

Neonatal hepatitis with presence of giant cells could have been caused by an infectious agent transmitted during pregnancy. The positive biphasic hemolysin exam performed prior to the corticotherapy also reinforces this possibility. However, in the last liver fragment obtained during splenectomy after a prolonged antibiotic therapy for *B. henselae*

and the after immunosuppressive drugs suspension, no signs of activity of hepatitis were found.

Severe anemia is a hallmark of Oroya fever, the febrile phase of Carrion's bartonellosis, caused by *B. bacilliformis*, and it has also been described in infections by *B. henselae*. This bacterium is also implicated in cryptogenic hepatitis, bacillary peliosis hepatitis, granulomatous and micro-abscesses in the liver⁹.

In the present case report *Bartonella* sp. infection was suggested by TEM, because they are the unique known intraerythrocytic bacteria. Later, *B. henselae* was confirmed by species-specific nested-*FtsZ*-PCR followed by confirmatory tests (enzyme restriction and automated DNA sequencing). The fact that the initial one-round *FtsZ*-PCR was negative could be attributed to a low bacteremia and a lack of sensitivity of the molecular test. Considering the positive nested-*FtsZ*-PCR obtained in three of eleven child's blood samples after seeding in culture media, if on one hand the patient was receiving prophylactic antibiotic to prevent urinary tract infections at the time of blood collection what could have reduced the bacterial load, on the other hand, in these three samples, albeit the dilution of the child's blood in culture media, the incubation of the blood samples in the culture bottles have probably favored the bacteria replication, therefore increasing the bacterial load. Moreover, one should expect a nested amplification to be more sensitive than a one-round PCR.

Another possibility that is worth to be mentioned is the acquisition of infection by blood transfusion from an asymptomatic donor. This hypothesis, although plausible, does not justify the child's anemia, jaundice and hepatosplenomegaly already present at birth. After the TEM detection of *Bartonella* sp. within erythrocytes in the blood bag donated by the mother, the Blood Bank discarded this bag, but as the mother was asymptomatic, it is likely that other blood donors could have asymptomatic infections caused by *Bartonella* spp. that are inadvertently transmitted to blood receivers.

Vertical transmission became more likely when the asymptomatic mother's blood revealed the presence of bacillary structures within rare RBC of the child's first liver biopsy performed on the 12th day of life, five months before the first blood transfusion had taken place.

Another point that merits discussion is the possibility of a domiciliary acquisition of infection by the child from infected cats. Once again, the TEM findings in the liver biopsy performed on the 12th day of life states against this hypothesis because the child had been hospitalized since birth until the fifth month of life.

The diagnosis of the mother's asymptomatic infection by *B. henselae* made by TEM and the nested-*FtsZ*-PCR, and the 100% of homology between the sequences obtained from the patient and her mother and the Houston-1 strain also reinforces the occurrence of a vertical transmission in the present case.

The existence of asymptomatic human hosts of *Bartonella* spp. was known, but the case presented herewith is relevant because it opens up the possibilities of other etiological agents to be associated with vertical transmission and potentially leading to intrahepatic neonatal cholestasis and hepatitis.

This case exemplifies a chronic inflammatory infectious process¹. Although the bacteria were visible in a liver fragment of the biopsy performed at 12 days of age, the use of high doses of immunosuppressant agents was able to normalize liver enzyme levels though the persistence of anemia.

Bartonellosis may be more frequent than previously thought. To date, we do not have a gold standard test to confirm *Bartonella* sp. infections in clinical practice, but the lack of considering the diagnostic hypothesis of infection by these bacteria still stands as the major limiting factor towards diagnosing new cases of this infection.

FUNDING

Fundo de Apoio ao Ensino, à Pesquisa e à Extensão (Faepex) 229/06.

REFERENCES

1. Velho PE, Cintra ML, Uthida-Tanaka AM, de Moraes AM, Mariotto A. What do we (not) know about the human bartonellosis? *Braz J Infect Dis*. 2003;7:1-6.
2. Breitschwerdt EB, Maggi RG, Chomel BB, Lappin MR. Bartonellosis: an emerging infectious disease of zoonotic importance to animals and human beings. *J Vet Emerg Crit Care (San Antonio)*. 2010;20:8-30.
3. Johnson R, Ramos-Vara J, Vemulapalli R. Identification of *Bartonella henselae* in an aborted equine fetus. *Vet Pathol*. 2009;46:277-81.
4. Bilavsky E, Amit S, Avidor B, Ephros M, Giladi M. Cat scratch disease during pregnancy. *Obstet Gynecol*. 2012;119:640-4.
5. Guptill L, Slater LN, Wu CC, Lin TL, Glickman LT, Welch DF, et al.. Evidence of reproductive failure and lack of perinatal transmission of *Bartonella henselae* in experimentally infected cats. *Vet Immunol Immunopathol*. 1998;65(2-4):177-89.
6. Boulouis HJ, Barrat F, Bermond D, Bernex F, Thibault D, Heller R, et al.. Kinetics of *Bartonella birtlesii* infection in experimentally infected mice and pathogenic effect on reproductive functions. *Infect Immun*. 2001;69:5313-7.
7. Breitschwerdt EB, Maggi RG, Farmer P, Mascarelli PE. Molecular evidence of perinatal transmission of *Bartonella vinsonii* subsp. *berkhoffii* and *Bartonella henselae* to a child. *J Clin Microbiol*. 2010;48:2289-93.
8. Mohle-Boetani JC, Koehler JE, Berger TG, LeBoit PE, Kemper CA, Reingold AL, et al. Bacillary angiomatosis and bacillary peliosis in patients infected with human immunodeficiency virus: clinical characteristics in a case-control study. *Clin Infect Dis*. 1996;22:794-800.
9. Velho PE, Pimentel V, Del Negro GM, Okay TS, Diniz PP, Breitschwerdt EB. Severe anemia, panserositis, and cryptogenic hepatitis in an HIV patient infected with *Bartonella henselae*. *Ultrastruct Pathol*. 2007;31:373-7.
10. Velho PE, de Moraes AM, Uthida-Tanaka AM, Cintra ML, Gigliogi R. Ultrastructural changes in a standard strain of *Bartonella henselae* after passages through BALB/cAn mice. *Ultrastruct Pathol*. 2002;26:161-9.
11. Magalhães RF, Cintra ML, Barjas-Castro ML, Del Negro GM, Okay TS, Velho PE. Blood donor infected with *Bartonella henselae*. *Transfus Med*. 2010;20:280-2.
12. Kelly TM, Padmalayam I, Baumstark BR. Use of the cell division protein FtsZ as a means of differentiating among *Bartonella* species. *Clin Diagn Lab Immunol*. 1998;5:766-72.
13. Kawasato KH, de Oliveira LC, Velho PE, Yamamoto L, Del Negro GM, Okay TS. Detection of *Bartonella henselae* DNA in clinical samples including peripheral blood of immune competent and immune compromised patients by three nested amplifications. *Rev Inst Med Trop Sao Paulo*. 2013;55:1-6.

14. Alagille D. Neonatal Hapatitis. In: Roy CC, Silverman A, Alagille D, editors. Pediatric Clinical Gastroenterology. 4th ed. St. Louis: Mosby; 1995. p. 620-35.
15. De Tommaso AM, Kawasaki AS, Hessel G. Paucity of intrahepatic bile ducts in infancy - experience of a tertiary center. *Arq Gastroenterol.* 2004;41:190-2.
16. Bernard O, Hadchouel M, Scotto J, Odievre M, Alagille D. Severe giant cell hepatitis with autoimmune hemolytic anemia in early childhood. *J Pediatr.* 1981;99:704-11.
17. Hicks J, Barrish J, Zhu SH. Neonatal syncytial giant cell hepatitis with paramyxoviral-like inclusions. *Ultrastruct Pathol.* 2001;25:65-71.
18. Ishak KG. Inherited metabolic diseases of the liver. *Clin Liver Dis.* 2002;6:455-79.
19. Gorelik M, Debski R, Frangoul H. Autoimmune hemolytic anemia with giant cell hepatitis: case report and review of the literature. *J Pediatr Hematol Oncol.* 2004;26:837-9.

Received: 07 December 2015

Accepted: 26 February 2016